

Research Journal of Pharmaceutical, Biological and Chemical Sciences

Assessment Of Functional Outcome Of Arthroscopic Anterior Cruciate Ligament Reconstruction Using Quadrupled Hamstring Tendon Autograft.

VL Narayanan^{1*}, T Sathish Kumar², and JPV Jebaraj³.

¹Associate Professor, Department Of Orthopedics, Panimalar Medical College Hospital & Research Institute, Poonamallee, Chennai, Tamil Nadu, India.

^{2,3}Assistant Professor, Department Of Orthopedics, Panimalar Medical College Hospital & Research Institute, Poonamallee, Chennai, Tamil Nadu, India.

ABSTRACT

The anterior cruciate ligament (ACL) is the most commonly injured ligament about the knee, with an increasing incidence of 22% between 2002 and 2014. For anterior cruciate ligament reconstruction (ACLR), hamstring autograft has become increasingly popular as a graft option, with noninferior retear rates or outcomes reported compared with other graft options. Hamstring diameters have been found to vary in mean folded graft diameter, with biomechanical studies showing that graft size affects ultimate failure load. Common techniques to increase graft diameter include allograft augmentation and quadruple-folding of the hamstring autograft, which form additional stranded grafts. To evaluate the Functional outcome of arthroscopic trans portal ACL Reconstruction with quadrupled hamstring graft. The prospective study of 38 patients treated with arthroscopic anterior cruciate ligament reconstruction with quadrupled hamstring graft at department of orthopaedics Panimalar Medical College Hospital & Research Institute, Poonamallee, Chennai, Tamil Nadu, India in the year April 2023. Right side was more predominant side to get injured with 58 % than left side which was 42%. ACL injuries were more commonly associated with medial meniscus injury was 21% , lateral meniscus was 10% and 8 % involving both MM and LM. Intra operatively there was no major complication faced. Post operatively, most of the cases had no complications and superficial infection was only complication faced with two patients which constituted only 5.3%. They were managed with antibiotics and there was no need for lavage. Sensory paraesthesia below the knee is seen in 26.3% of our patients. Final results were excellent in 53%, good in 32% and fair in 15%. Pre operatively and post operatively for periodically 6 months, all patients were analysed with IKDC score , the pretest mean and standard deviation was found to be at 41.24 and 3.38 while post-test mean and standard deviation was at 57.45 and 1.87 and the mean difference was 16.21. With modern surgical and fixation devices, excellent clinical results can be obtained with quadrupled hamstring grafts. The principles of surgical technique, graft choice, graft fixation, and postoperative rehabilitation are more important in anterior cruciate ligament reconstruction. Titanium RCI interference screw results are good providing cheaper alternative for our patients

Keywords: Anterior cruciate ligament, Arthroscopic anatomical reconstruction, Biointerference screw.

<https://doi.org/10.33887/rjpbcs/2024.15.2.63>

**Corresponding author*

INTRODUCTION

Sustaining an injury in ones lifetime is a common phenomenon. The most common etiology of knee injury happens during sports, recreational activity, work or home related tasks. The knee being the largest joint in the body and most of the problem related to knee is not only caused by direct injury, it has other multifactorial causes. Osteoporosis, arthritis, aging factor, various activities including sports, recreation, job may aggravate an existing knee injury or may be root cause for its incidence [1]. The most common purpose one seeks a doctor is due to knee injury which roughly accounts to 10.4 million in 2010 due to various cause like fractures, sprains, dislocations and ligament tears [2]. Incidence of ACL injuries is always higher among people indulging in various high risk sports activity like basketball, football, skiing, and soccer [3-5]. Which is roughly estimated annually around 200,000 individuals. Annually the number of ACL reconstruction is on the rise which constitutes around 100,000 cases per year [6, 7]. Amongst the cruciate ligaments, the ACL has the highest incidence of involvement to injury. The reason mainly being indulging in high demand activities. In addition to isolated ACL injury it occurs in combination with other structural involvement like the meniscus, cartilages and other ligaments which accounts for 50% of injuries [8, 9]. Female athletes sustaining ACL injury outnumbers male athlete, the reason being differences in physical build which includes pelvis and alignment of lower extremities, physical conditions, neuromuscular control, effect of estrogen, increased laxity and tensile strength on the ligaments [2, 5, 10]. ACL injury occur either due to direct contact or by indirect contact mechanism. The direct contact accounts to 30 percent while indirect mechanism results around 70 percent of all ACL injuries which is commonly associated deceleration along with awkward maneuvers [4, 11-13]. Patient experiences severe pain, swelling, loss of movements, tenderness and instability while walking. ACL reconstruction has not been in limelight until 1970's since its surgical complexity was a challenge to surgeons who were very choosy in selecting the procedure for the needed patients. The advancement in the field of arthroscopy and operative techniques mainly by Jackson and Dandy opened the door for ACL reconstruction within the field of interest of the surgeons. The single bundle procedure has proven to be a boon for operating surgeons in restoring the functionality of the knee. Restoration of consolidated intra and extra articular techniques alongside solid pre and post agent appraisal instruments give better consistence, assessment and long haul results. A definitive objective of current ACL reconstruction surgery goes for re establishing ordinary knee kinematics and usefulness of the knee joint. Hence this study was undertaken to assess the functional outcomes of ACL reconstruction surgery to bring an insight in the advancement in arthroscopic surgeries.

MATERIALS AND METHODS

The prospective study of 38 patients treated with arthroscopic anterior cruciate ligament reconstruction with quadrupled hamstring graft at Department of orthopaedics, Panimalar Medical College Hospital & Research Institute, Poonamallee, Chennai, Tamil Nadu, India in the year April 2023.

Inclusion Criteria

- Patients who are in the age group of 18-60 years of age, who were functionally active prior to injury.
- Patients of either sex
- Patients with isolated ACL injury or with a meniscal injury on MRI.
- Patients consenting for a surgical intervention
- Patients with a sound mind
- Patients who agree for follow up

Exclusion Criteria

- Patients not consenting for a surgical intervention.
- Patients not of sound mind.
- Admitted for revision surgery.
- Patients who do not agree for a follow up.
- Skeletally immature individuals.
- Severe Osteoarthritic changes
- Coexisting ligament injury such as the posterior cruciate, collateral ligament injury.

Arthroscope

Arthroscope forms the heart of the arthroscopic system consisting an eyepiece, a light cable with attachment, lenses and optical fibre for transmitting light. The arthroscopic barrel consist of the lenses, metal casting and fiberoptics. Various viewing angle arthroscopies are available such as 00-forward view scope, 300wide angle and 700 wide angle. Depending on the visualizing space to be explored the arthroscopic diameter range from 2.7 to 7.5 mm. In our study we have used Starz arthroscope with 300 prism with 4mm diameter for reconstruction of the anterior cruciate ligament.

Tourniquet Placement

Pneumatic tourniquets are usually placed at the proximal third of the thigh. The tourniquet should be applied more proximally if the thigh is shorter and thicker if reconstruction of ACL is the option. Usually it is applied just prior to induction of general anaesthesia regardless of inflation status during surgical procedure.

Implants

Direct devices like interference screws and washers mainly provide an option for soft tissue grafts in femur. Fixation by means of indirect devices include endobutton, femoral cross pins, suture discs and anchors are an option. Endobuttons which are more advanced are available today which provide finest fixation of graft at the femoral side. The cross pins were ideally an alternative to cortical suspensory and joint line fixation. Tibial fixations are mainly interference screws, staples, screw and washer. In this study endobutton for femoral fixation and titanium interference screws for tibia were used.

Preoperative Work Up

Before embarking any surgical procedures for reconstruction of ACL tear it is mandatory to document the abnormality in laxity and to visualise the bony abnormality by radiography. Any insufficiency in ACL injury should be assessed by proper history taking and symptomatology of the injured knee. Hence patient clinically proven to sustain ACL injury by various test and by radiographic assessment including MRI were admitted at department of Orthopaedics and Traumatology. Blood investigations including complete blood count, blood serology, renal parameters, chest x ray, ECG were done as part of preop investigation. Anaesthetic opinion for regional and general anaesthesia were obtained. Knowledge on how to perform static and dynamic quadriceps were taught to the patient on prior to surgery including awareness for post operative physiotherapy.

Post Operative Management

Immobilization in knee supports and elevation of limb post operatively.

- Intravenous antibiotics for 3 doses.
- Drain expulsion on first post operative day.
- Wound assessment on 2,5 Postoperative day.
- Suture evacuation on 10th Postoperative day.

Rehabilitation

Post Operative Rehabilitation

Tremendous changes have been undergone in ACL rehabilitation over the past decade .With improved techniques, intensive biomechanics research and encouraging results about graft healing has lead to advanced and aggressive rehabilitation. Previous techniques like delayed weight bearing , post operative casting and limitations of ROM have been outcast by immediate training of ROM and weight bearing exercises which are included in the current early rehabilitation program

RESULTS

A total of 38 cases sustaining ACL injury underwent arthroscopy assisted transportal reconstruction of anterior cruciate ligament using quadrupled hamstring tendon graft were followed for six months to 1.5 years .The mean follow up was 10.5 months.

Table 1: Tabular column showing pre and post test score according to IKDC score

	Mean	SD	SE	difference in means	t-test	p-value
Pre-test	41.24	3.38	0.55	11.47	19.21	<0.0001*
Post-test	52.71	4.26	0.69			

Figure 1: Whisker box diagram showing pre and post test score according to IKDC score

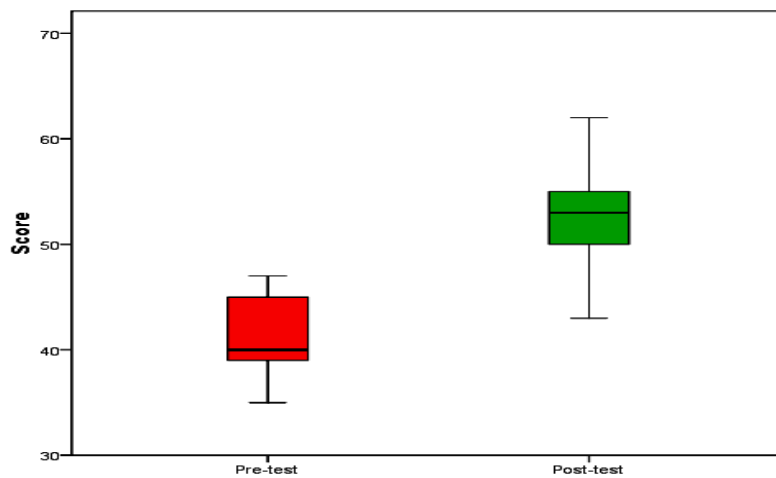
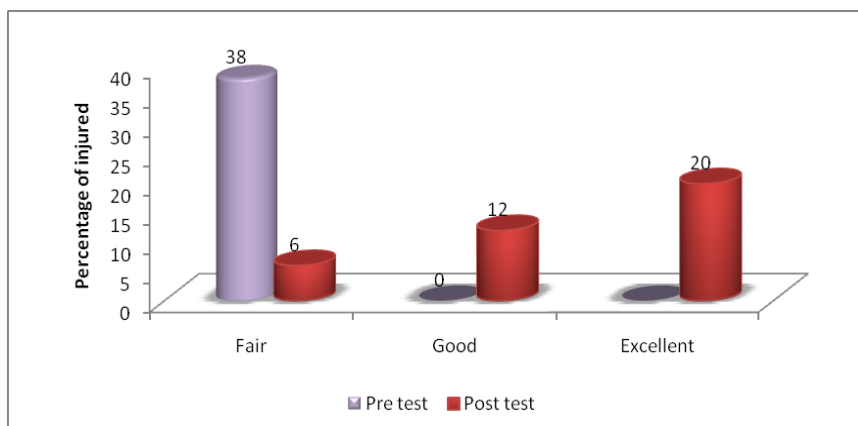


Table 2: Association between associated injury and results.

Associated Injury	Results			Total	chi-square	P value
	Excellent	Good	Fair			
Medial meniscus tear	4 (50%)	2 (25%)	2 (25%)	8 (21.1%)	14.437	0.025*
Lateral meniscus tear	2 (50%)	2 (50%)	0 (0%)	4 (10.5%)		
Both	1 (25%)	0 (0%)	3 (75%)	4 (10.5%)		
NIL	13 (59.1%)	8 (36.4%)	1 (4.5%)	22 (57.9%)		
Total	20 (52.6%)	12 (31.6%)	6 (15.8%)	38 (100%)		

Figure 2: Scoring of patients according to IKDC score according to 9th month



DISCUSSION

The most commonest cause for the injury to anterior cruciate ligament is either due to sports injury or road traffic accidents which is on the rise every year. The gold standard in sports medicine has been the arthroscopic anterior cruciate ligament reconstruction. Surgery usually provides a full functional knee with providing better stability which in future prevents possible complications like arthritis and repeated knee injury [11]. Post traumatic osteoarthritis, muscle weakness and joint instability are the frequent complications of an operated anterior cruciate ligament injury. In the whole of the musculoskeletal system, anterior cruciate ligament is one of the most interested area of research during the last 25 years. Among the cruciate ligaments the anterior cruciate ligament appears to be the weaker and more vulnerable to injury [12]. Clinical outcomes are greatly dependent on graft placement since it may lead to pain, functional loss of movements, failure of graft, impingement and even arthritis if the located of the tunnel is not accurate. About 10 to 20% of high revision rate is noted by American Orthopedic Society for Sports Medicine (AOSSM). Even expert surgeons have faced difficulties in tunnel placement which have been documented by various studies [13]. Advancement in arthroscopic instrumentation and surgical techniques has lead to increased frequency of autologous grafts along with graft fixation and rehabilitation which have increased the functional recovery [14]. The ability to have multiple views to visualise the joint makes the arthroscopy to excel than open procedures. In depth understanding of the morphology of the anterior cruciate ligament is the basic for its anatomical reconstruction. ACL drew attention and various pioneers in this topic evolved with various scientific articles were published on ACL reconstruction and its outcomes. The ultimate goal was to restore the kinematics of the patients knee joint which confers stability to the knee joint and thereby reducing long term chondrosis. Our study is to evaluate the functional outcome of arthroscopic ACL reconstruction using quadrupled hamstring tendon autograft [15]. In our study, road traffic accidents injury predominate as the major cause of injury which accounts for 47% while fall and sports trauma accounts for 24% and 29% respectively. Alcohol influence was found among 28.9% patients at time of injury while 55.3% patients are addicted to alcohol which accounts for high level of RTA in our study. In our study meniscal injury was found to be around 32% which is quite similar to other studies where medial meniscus injury was on higher range than lateral meniscus. This fact was true with most of the other studies like the one described by DW Lewis where he reported 58% of meniscal involvement at presentation, and also resection or repair did not affect the outcome. He also predicted for better functional outcomes in which chondral lesions play a vital part [16]. The selection of the right graft has been a topic of debate since each graft has its own merits and demerits. An ideal graft which is used for ACL reconstruction should be able to recreate the anatomical and biochemical properties similar to the native ligament, provide safe fixation, integration biologically, should reduce recovery phase and morbidity of the donor site. Throughout the decades autogenous, allogenic and engineered grafts have been created notwithstanding routine grafts like bone patellar ligament bone graft, hamstring graft, quadriceps ligament graft. Great elasticity. When he distributed his work with respect to histological examination of delicate tissue recuperating in an animal study that lasted for 12 weeks duration. Ballal described that operative results on ACL reproduction were better with a quadrupled semitendinous graft which contributed viable general knee steadiness in profound flexion and keeping up a similar quality amid inside pivot [17]. Comparative outcomes with same inconvenience with utilization of patellar ligament joint. Actually, few studies depicted patellar bone ligament had an edge over hamstring ligament joint utilized for ACL reconstruction with regard to laxity of the knee, pivot-shift grade, and flexor muscles strength of the knee. The surgeon usually determines the graft diameter when using a patellar bone tendon graft while the hamstring tendon diameter is devoid of any influence from the surgeon [18]. Graft length is critical for adequate femoral and tibial fixation which is usually 7mm. Before the graft integration at the rehabilitation phase, irrespective of the graft type, the failure is due to graft fixation rather than its type and its insignificant after 8 to 12 weeks if the graft has integrated with the bone. decrease in tensile strength and stiffness were the major concern while using fixation devices with soft tissue grafts since they were more prone for slippage when compared to interference screws used for bone patellar tendon grafts. Hence over the past decade, various improvisation in the types of fixation devices have been increased in the usage of soft tissue grafts in ACL reconstruction. Many biomechanical studies have found solution to avoid slippage and fasten circumferential tendon healing by using fixation devices with high strength and stiffness. Owing to its biocompatibility, titanium screws were the first line used in ACL reconstruction [19]. They latter gave way to bio absorbable screws since they get reabsorbed automatically in the body. The major drawback of titanium screws are that they are prone for infection, may require a second surgery for its removal while bio absorbable screw are expensive, may lead to foreign body reaction, incomplete formation of bone and forms graft tissue at slower rate. Poly-L-lactic

acid with hydroxyapatite (PLLA-HA) screw did not cause cyst formation or widening of tunnel after a five year follow up study done. In our study we used titanium screw for tibial fixation and endobutton for femoral fixation. Even though there were disadvantages with both these fixation devices like tunnel widening, displacement of graft etc, we did not infer any graft failure post operatively during rehabilitation phase. In our study we used transportal single bundle reconstruction with quadrupled hamstring graft [20]. In our findings around 53% of patient had excellent outcomes, 32% had good result while 15% had a fair post operative result. 85% of patients had a There was 5 degree extensor slack and 10% insignificant anteroposterior laxity in around ¼ of our patients. Riley et al in their audit demonstrated just 85 extensor slack and 11% positive pivot shift. They additionally detailed that arthroscopic joint lavage was provide for 2% of their patient because of post operative contamination which was one of the normal exhibiting inconveniences [21]. In our case, superficial infections were marginally higher, around 5% treated by antibiotics for a period of five days which did not warrant for a rewash, as the superficial infection were completely cured after antibiotic instillation [22]. Quadriceps strengthening exercises, knee flexion exercises were insisted to our patients as part of post operative physiotherapy program. Home based physiotherapy programme was considerably effective when compared to supervised programmes as it was found to cost effective Even though accordingly to the IKDC scoring, the post-test scored fair for 6 patients, these patients were found to be addicted to alcohol that limited them to have a complete follow up which could have been better if they have had their reviews regularly [23-25].

CONCLUSION

The technique of arthroscopic ACL reconstruction using quadrupled hamstring tendon autograft, has little morbidity, no reoperation rate and excellent clinical results in short term. With modern surgical and fixation devices, excellent clinical results can be obtained with quadrupled hamstring grafts. The principles of surgical technique, graft choice, graft fixation, and postoperative rehabilitation are more important in anterior cruciate ligament reconstruction. Titanium RCI interference screw results are good providing cheaper alternative for our patients

REFERENCES

- [1] Arendt E, Dick R. Knee Injury Patterns Among Men and Women in Collegiate Basketball and Soccer: NCAA Data and Review of Literature. *Am J Sports Med* 1995;23(6):694-701
- [2] Griffin LY. Noncontact Anterior Cruciate Ligament Injuries: Risk Factors and Prevention Strategies. *J Am Acad Orthop Surg* 2000; 8:141-150
- [3] Viola RW, Steadman JR, Mair SD, et al. Anterior Cruciate Ligament Injury Incidence Among Male And Female Professional Alpine Skiers. *Am J Sports Med* 1999; 27:792-795.
- [4] Miyasaka KC, Daniel DM, Stone ML. The incidence of knee ligament injuries in the general population. *Am J Knee Surg* 1991; 4:43-48
- [5] Brown CH, Carson EW. Revision anterior cruciate ligament surgery. *Clin Sports Med* 1999;109-171
- [6] Graf B, Cook D, De Smet A, et al. "Bone bruises" on Magnetic Resonance Imaging Evaluation Of Anterior Cruciate Ligament Injuries. *Am J Sports Med* 1993;21(2):220-223
- [7] Johnson DL, Urban WP, Jr, Caborn DNM, et al. Articular Cartilage Changes Seen With Magnetic Resonance Imaging-Detected Bone Bruises Associated with Acute Anterior Cruciate Ligament Rupture. *Am J Sports Med* 1998;26(3):409-414
- [8] Ireland ML. Anterior Cruciate Ligament Injury in Female Athletes: Epidemiology. *Journal of Athletic Training* 1999;34(2):150-154
- [9] Kirkendall DT, Garrett WE. The anterior cruciate ligament enigma. Injury mechanisms and prevention. *Clin Orthop* 2000;372:64-68
- [10] Yu B, Kirkendall DT, Taft TN, et al. Lower extremity motor control-related and other risk factors for noncontact anterior cruciate ligament injuries. *Inst Course Lect* 2002; 51:315-324
- [11] Colby S, Francisco A, Yu B, et al. Electromyographic and Kinematic Analysis of Cutting Maneuvers: Implications for Anterior Cruciate Ligament Injury. *Am J Sports Med* 2000;28(2):234-240.
- [12] Miller RH, Azar FM. Sports medicine: knee injuries. In: Canale ST, Beaty JH, eds. *Campbell's Operative Orthopaedics*. Philadelphia, PA: Mosby Elsevier; 2008.

- [13] Petersen W, Laprell H. Insertion of autologous tendon grafts to the bone: a histological and immunohistochemical study of hamstring and patellar tendon grafts. *Knee Surg Sports Traumatol Arthrosc* 2000;8(1):26-31.
- [14] Zantop T, Petersen W, Sekiya JK, Musahl V, Fu FH. Anterior cruciate ligament anatomy and function relating to anatomical reconstruction. *Knee Surg Sports Traumatol Arthrosc* 2006;14(10): 982-992.
- [15] Petersen W, Tillmann B. [Anatomy and function of the anterior cruciate ligament. *Orthopade* 2002;31(8):710-718.
- [16] Tena-Arregui J, Barrio-Asensio C, Viejo-Tirado F, Puerta-Fonolla J, Murillo-Gonzalez J. Arthroscopic study of the knee joint in fetuses. *Arthroscopy* 2003;19(8):862-868.
- [17] Ellison AE, Berg EE. Embryology, anatomy, and function of the anterior cruciate ligament. *Orthop Clin North Am* 1985;16(1):3-14.
- [18] Lohmander LS, Ostenberg A, Englund M, Roos H. High prevalence of knee osteoarthritis, pain, and functional limitations in female soccer players twelve years after anterior cruciate ligament injury. *Arthritis Rheum* 2004;50(10):3145-3152.
- [19] Girgis FG, Marshall JL, Monajem A. The cruciate ligaments of the knee joint. Anatomical, functional and experimental analysis. *Clin Orthop Relat Res* 1975; 106:216-231.
- [20] Zantop T, Petersen W, Sekiya JK, Musahl V, Fu FH. Anterior cruciate ligament anatomy and function relating to anatomical reconstruction. *Knee Surg Sports Traumatol Arthrosc* 2006;14(10): 982-992.
- [21] Amis AA, Dawkins GP. Functional anatomy of the anterior cruciate ligament. Fibre bundle actions related to ligament replacements and injuries. *J Bone Joint Surg Br* 1991;73(2):260-267.
- [22] Girgis FG, Marshall J L, Monajem A. The cruciate ligaments of the knee joint. Anatomical, functional and experimental analysis. *Clin Orthop Relat Res* 1975; 106:216-231.
- [23] Harner CD, Livesay GA, Kashiwaguchi S, Fujie H, Choi NY, Woo SL. Comparative study of the size and shape of human anterior and posterior cruciate ligaments. *J Orthop Res* 1995;13(3):429-434.
- [24] Harner CD, Baek GH, Vogrin TM, Carlin GJ, Kashiwaguchi S, Woo SL. Quantitative analysis of human cruciate ligament insertions. *Arthroscopy* 1999;15(7):741-749.
- [25] Zaffagnini S, Golano P, Farinas O, Depasquale V, Strocchi R, Cortecchia S, et al. Vascularity and neuroreceptors of the pes anserinus: anatomic study. *Clin Anat* 2003;16(1):19-24.